

Endometroid Carcinoma of Ovary - A Rare Malignancy

Ramadas P Chadaga, Shabina Inayath

Obstetrics & Gynaecology Department, Kasturba Medical College, Light House, Hill Road, Mangalore, Karnataka

Mrs. M. 55 yrs, P₃ L₃ all FTND, presented to Gynaec OPD with Polymenorrhagia-7 months & weakness & loss of appetite. Her menarche was at 13th yr. LCB was 13 years ago. On examination she was moderately built and nourished with severe anaemia. P/A - A mass arising from the pelvis, corresponding to 16 weeks pregnant uterus, firm, irregular non tender with restricted mobility was present. No other organomegaly or ascitis seen. P/S - showed Cervical erosion. Anterior fornix fullness was noted. Bimanual examination revealed an irregular uterus of 16 weeks size. P/R - POD nodularity not found. Investigations- Hb-6gm%, USG-a right adnexal cystic mass with mixed echogenicity & confirmed a 16x14 cm fibroid uterus. Anaemia was corrected.

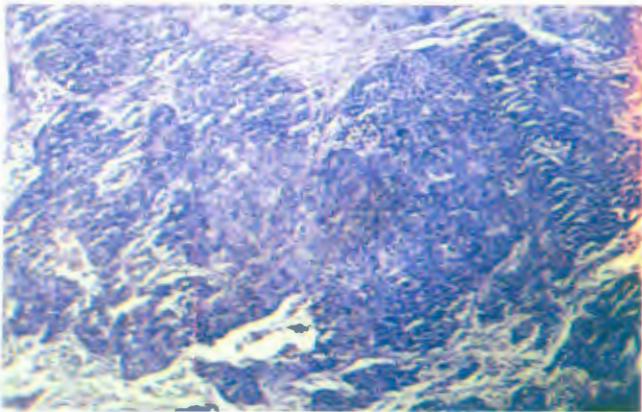


Figure 1: Low power field - shows a tumour made up of round cells with scanty moderate eosinophilic cytoplasm having large pleomorphic nuclei arranged in sheets.

With a provisional diagnosis of fibroid uterus a laparotomy was done - adhesions of large bowel on right side present. A right ovarian cyst of 6x7cm with solid component & containing chocolate like material was

removed with tube along with TAH & left Salpingo-oophorectomy. Omentectomy was done in view of her age & possibility of an ovarian malignancy. HPE revealed Endometroid Ca of ovary, Fibroid uterus & endometriotic cyst of ovary, with malignant implants in the fallopian tube. (Fig. 1 & Fig. 2) In view of stage II Ca of the ovary, she underwent chemotherapy with Inj Cyclophosphamide 750mg & Inj carboplatinum 370mg for 6 cycles.

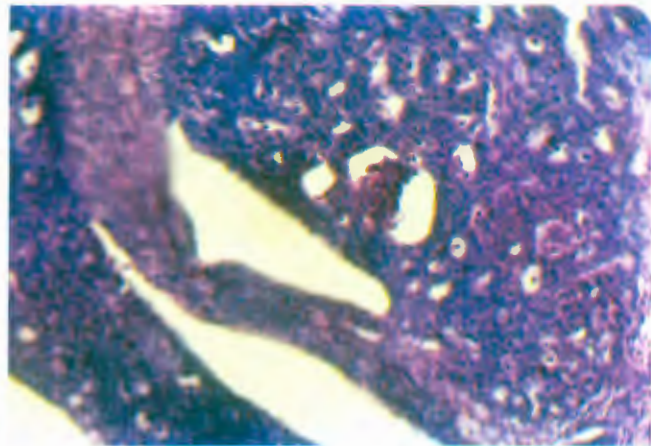


Figure 2: High power field - shows a tumour made up of round cells with scanty moderate eosinophilic cytoplasm having large hyperchromatic nuclei arranged in glandular pattern.

7 months after treatment patient was in good health with no evidence of immediate metastasis. She is being followed up.